

Pathogenic *Escherichia fergusonii* and *Staphylococcus gallinarum* co-infection in a free-ranging domestic chicken

Gerald Misinzo¹, Coletha Mathew², Ramadhan Matondo², Fatuma Jumapili¹, Makolo Ludosha¹, Seleman Masola³, Wilfred Munisi³, Wesley Viaene⁴ and Jan Van Doorselaere⁴

¹Departments of Veterinary Microbiology and Parasitology and ²Veterinary Pathology, Faculty of Veterinary Medicine, Sokoine University of Agriculture, Morogoro, Tanzania; ³National Livestock Research Institute, Mpwapwa, Tanzania; and ⁴Higher Institute for Nursing and Biotechnology, Catholic University College, Roeselare, Belgium

Abstract

Examination was carried out in an emaciated and depressed free-range domestic chicken from Mpwapwa where multiple cases of a similar condition were observed in 2010. A loosely attached unilateral nodule on the ventral aspect of the right eye and similar other nodules around the base of feathers mainly on dorsal aspects of wings, neck and head were observed. The cut nodules were yellowish with a firm and cheesy consistency surrounded by hyperaemic skin. In addition, multiple grey foci of variable size on liver and localized areas of hyperaemia on duodenal mucosa with mucoid exudates in the lumen were observed. On histopathology, the nodular lesions consisted of hyperplastic feather follicles with broad bands of keratinocytes and extension of follicular epithelium into surrounding dermis. In addition, luminal folliculitis in the skin and hepatic portal vasculitis were observed. Excised lesions from the eye, skin and liver were streaked on bacteriological agar with or without penicillin and streptomycin to isolate bacteria. Bacteria grew in agar without antibiotics but not in agar containing antibiotics. Bacterial colonies were subcultured and passaged four times to obtain pure cultures. Based on colony morphology, two types of bacteria were isolated from each of the organs. DNA was extracted from bacteria followed by amplification and sequencing of the 16S rDNA using 27F and 1492R primers. Sequence similarity search in GenBank showed that the bacteria were *Escherichia fergusonii* and *Staphylococcus gallinarum*. The present study shows that the chicken had *E. fergusonii* and *S. gallinarum* co-infection sensitive to penicillin and streptomycin.

Keywords: *Escherichia fergusonii*, *Staphylococcus gallinarum*, 16S rDNA, co-infection

To cite this article: Misinzo G, C Mathew, R Matondo, F Jumapili, M Ludosha, S Masola, W Munisi, W Viaene and J Van Doorselaere, 2012. Pathogenic *Escherichia fergusonii* and *Staphylococcus gallinarum* co-infection in a free-ranging domestic chicken. Res. Opin. Anim. Vet. Sci., 2(5), 324-328.

Introduction

Escherichia fergusonii belongs to the family *Enterobacteriaceae* (Farmer et al., 1985). *E. fergusonii* are gram-negative bacteria that are generally motile. *E. fergusonii* is an emerging human and animal pathogen that has recently been associated with acute cystitis (Savini et al., 2008), wounds (Mahapatra et al., 2005), cancer (Lai et al., 2011) in humans and diarrhea (Hariharan et al., 2007) in animals. Pathogenic and multidrug-resistant *E. fergusonii* has been isolated from

chickens (Forgetta et al., 2012), pigs (Rayamajhi et al., 2011) and humans (Savini et al., 2008).

Staphylococcus gallinarum is a gram-positive bacteria originally isolated from skin of a chicken (Devriese et al., 1983). Although *S. gallinarum* is not generally pathogenic, it has been isolated from human patients (Kolawole & Shittu, 1997; Morfin-Otero et al., 2012; Tibra et al., 2010; Yu et al., 2008). *S. gallinarum* has been proposed to be one of the aetiological agents of bumblefoot disease in poultry sensitive to penicillin, chloramphenicol and sulphafurazole (Mohamed and El

Corresponding author: Gerald Misinzo, Department of Veterinary Microbiology and Parasitology, Faculty of Veterinary Medicine, Sokoine University of Agriculture, Morogoro, Tanzania

Sanousi, 1998). Poultry infected with *S. gallinarum* show depression, anorexia, fever and acute tenosynovitis with periportal infiltration of lymphocytes and heterophils, proliferative glomerular nephritis, haemorrhages and haemolysis (Mohamed and El Sanousi, 1998).

Herein, we describe the isolation of *E. fergusonii* and *S. gallinarum* from multiple organs in a free-ranging domestic chicken.

Materials and Methods

Clinical and post-mortem examination

An adult female emaciated and depressed free ranging chicken was submitted for examination at Sokoine University of Agriculture from Mpwapa in Tanzania. Similar clinical manifestation has been observed in other chickens in the same flock, other flocks in the same village and several other villages in Mpwapa District. Clinical examination was carried out followed by euthanasia and post-mortem examination.

Histopathology

Samples were preserved in 10% neutral buffered formalin and subsequently embedded in paraffin wax. Haematoxylin and Eosin staining was done on 5 µm thick tissue sections. Histological tissue sections were examined under a light microscope attached with a digital camera.

Isolation of bacteria

Nodules from the eye and the skin and a piece of the liver were flamed within a biological safety cabinet (BH-EN 2006, Fastei S.r.l., Ferrara, Italy). Afterwards, each tissue was cut using a sterile scalpel blade and smeared onto the surface of bacteriological agar (Oxoid Ltd., Hampshire, England) plated with or without antibiotics (penicillin and streptomycin). Bacteria were sub-cultured three times in bacteriological agar without antibiotics to obtain pure cultures.

Identification of bacteria

Bacteria were identified using 16S rDNA PCR followed by sequencing. Briefly, DNA from individual bacterial colonies was extracted using NucleoSpin columns following manufacturer's instructions (Macherey-Nagel, Düren, Germany). Afterwards, PCR was performed using the universal bacteria amplification forward primer 27F (5'-AGAGTTTGA TCMTGGCTCAG-3', where M is A or G) and reverse primer 1492R (5'-GGTACCTTGTTACGACTT-3') as previously described by Galkiewicz and Kellogg, 2008. Visualization of the PCR amplicons was done under a UV transilluminator after performing agarose gel electrophoresis and SBYR green I nucleic acid gel

staining (Roche Diagnostics GmbH, Mannheim, Germany). PCR products were treated with exonuclease I (New England Biolabs, Ipswich, MA, USA) to remove unused single stranded primers and Antarctic phosphatase (New England Biolabs) to remove unused dNTPs and subsequently used for dideoxynucleotide cycle sequencing. Sequencing PCR was performed using a Big Dye Terminator Cycle sequencing kit V1.1 (Applied Biosystem, Foster City, CA, USA). Products from cycle sequencing reaction were purified by ethanol precipitation and separated by capillary electrophoresis (ABI Prism 310 Genetic Analyser, Applied Biosystems). Sequence similarity search of the obtained 16S rDNA sequences was performed against the GenBank database using the Basic Local Alignment Search Tool (BlastN at <http://blast.ncbi.nlm.nih.gov>).

Results

Gross pathological examination results

The chicken had prominent keel, thin muscular layer on the brisket, and loosely attached unilateral swelling on the ventral aspect of the right eye were observed (Figure 1A). In addition, the chicken had several small loosely attached cutaneous nodules around the base of the feather on the dorsal aspects of the wings, neck and head. The nodules had firm consistency on cutting and characteristic yellowish colour and cheesy consistency on the cut surface (Fig. 1B). The skin enclosing the swelling was hyperaemic on the inner surface (Fig. 1B). Furthermore, multifocal grey spots of variable sizes on the liver (Fig. 1C) and localized areas of hyperaemia on the duodenal mucosa with mucoid exudates in the lumen were observed.

Histopathology

Nodular lesions at the base of the feathers consisted of hyperplastic feather follicle with broad bands of keratinocytes and extension of follicular epithelium into the surrounding dermis. Skin enclosing nodular swelling removed around the eye showed similar histopathological features as described above especially around the base of the feather follicle. All skin nodules showed characteristic luminal folliculitis with heterophils and lymphocytes in the walls of feather follicles (Figure 2A). Microscopic examination of the duodenal mucosa showed necrosis and shortening of the villi as well as infiltration of inflammatory cells comprised of heterophils and lymphocytes (Figure 2B). Similar inflammatory cells were also visible around portal blood vessels in the liver.

Microbiological examination

Excised lesion from the eye, skin and liver were streaked on bacteriological agar with or without overnight at 37 °C and bacterial colonies were

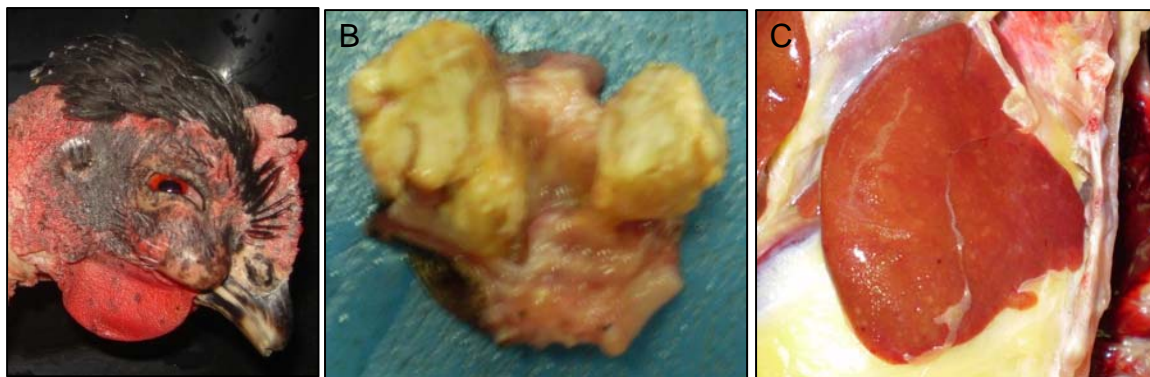


Fig. 1: Gross pathological lesions. (A) A swelling located between the ventral aspect of the eye and caudal to the beak, (B) The swelling seen in (A) after being excised from the chicken and (C) liver showing multifocal gray spots on its surface.

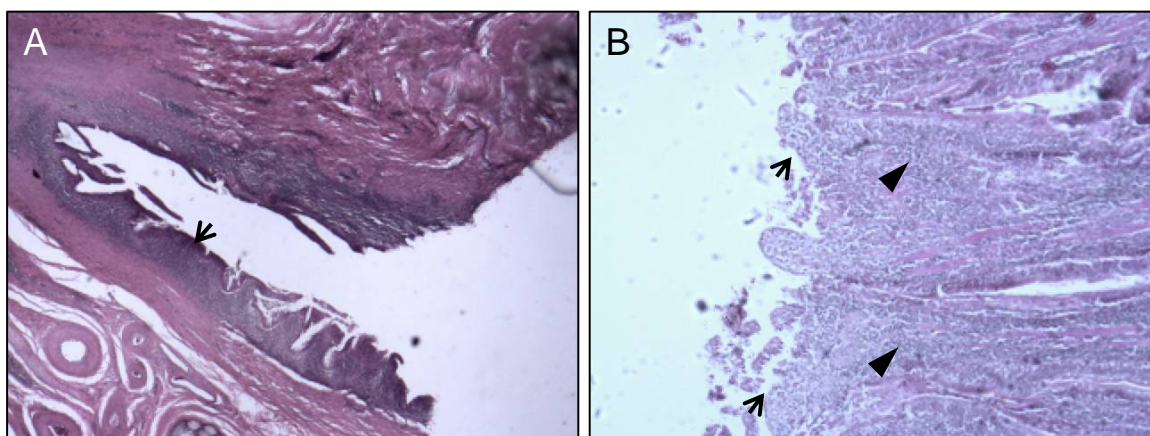


Fig. 2: Histopathological sections of the skin and intestines. (A) Luminal folliculitis in the skin (arrow). (B) Necrosis, shortening of the villi (arrow) and infiltration of inflammatory cells in intestinal epithelia (arrow head).

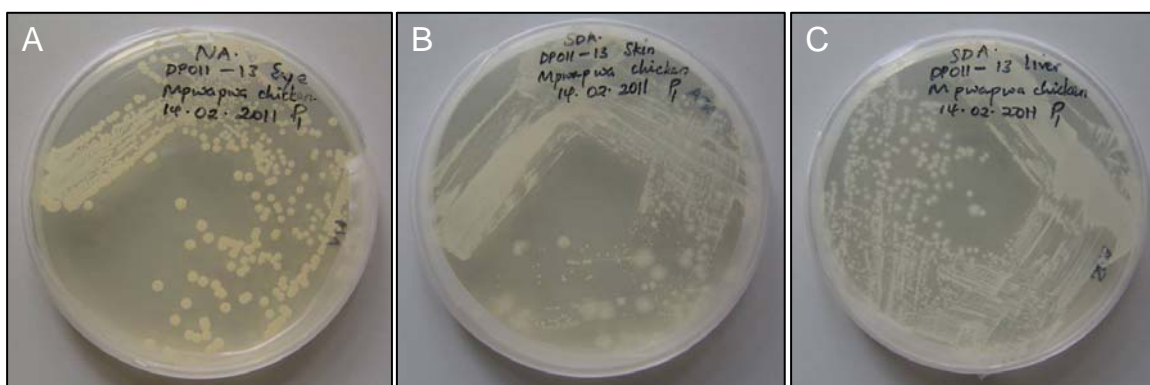


Fig. 3: Pure cultures of bacteria isolated from the cut surfaces of the nodules below the eye (A), on the skin (B) and the liver (C). The bacteria colonies in (B) and (C) spread on the surface of the agar indicating motility of the isolated bacteria. 16S rDNA analysis showed that bacteria in (A) are *Staphylococcus gallinarum* while that in (B) and (C) is *Escherichia fergusonii*.

subcultured and passaged four times in agar without antibiotics to obtain pure cultures. Based on colony morphology, two types of bacteria were isolated from the eye, skin and liver (Fig. 3). No bacteria were isolated from plates containing antibiotics indicating that the bacteria were sensitive to penicillin and streptomycin.

Identification of bacteria

DNA was extracted from the two distinct bacteria colonies isolated from liver and skin followed by amplification of the 16S rDNA using 27F and 1492R primers. PCR products migrated to approximately 1,500 bp after agarose gel electrophoresis, an expected size of the 16S rDNA amplicon for bacteria. PCR amplicons were then sequenced and the obtained sequences were blasted in GenBank using BlastN. Blast results indicate that the bacteria isolated from the chicken closely resembled 16S rDNA sequences of *Escherichia fergusonii* (Accession numbers HQ214033.1; nucleotide identities = 516/517 (99%) and gaps = 0/517 (0%)) and *Staphylococcus gallinarum* (Accession numbers HM209753.1; nucleotide identities = 477/480 (99%) and gaps = 2/480 (0%)). The 16S rDNA sequences of *E. fergusonii* and *S. gallinarum* obtained in this study have been deposited in GenBank with accession numbers JX226073 and JX226074, respectively.

Discussion

In the present study, *E. fergusonii* and *S. gallinarum* were isolated from a free-ranging domestic chicken with follicular hyperplasia, folliculitis, enteritis and hepatic portal vasculitis. To our knowledge, this is the first study that describes pathogenic *E. fergusonii* and *S. gallinarum* co-infection in avians. Pathogenic *E. fergusonii* and *S. gallinarum* have been previously isolated separately from avians (Forgetta et al., 2012; Devriese et al., 1983; Mohamed and El Sanousi, 1998). Systemic spread of *E. fergusonii* and *S. gallinarum* in avians leading to pathological changes in different visceral organs including liver, lungs, and kidney have previously been reported (Mohamed and El Sanousi, 1998; Herráez et al., 2005), in agreement with the findings presented in this study.

Both *E. fergusonii* and *S. gallinarum* are considered to be emerging pathogens affecting both animals and humans (Forgetta et al., 2012; Freney et al., 1987; Hariharan et al., 2007; Kolawole & Shittu, 1997; Lai et al., 2011; Mahapatra et al., 2005; Mohamed and El Sanousi, 1998; Morfin-Otero et al., 2012; Rayamajhi et al., 2011; Savini et al., 2008; Tibra et al., 2010; Yu et al., 2008). The zoonotic nature of these bacteria may have significant impact to public

health. Whether poultry acquired *E. fergusonii* and *S. gallinarum* from humans could not be established in this study.

The sensitivity of *E. fergusonii* and *S. gallinarum* to commonly used antibiotics is variable with some isolates being multidrug-resistant (Forgetta et al., 2012; Mohamed and El Sanousi, 1998; Rayamajhi et al., 2011; Savini et al., 2008). The *E. fergusonii* and *S. gallinarum* isolated in the present study were sensitive to both penicillin and streptomycin. Findings in this study will provide basic knowledge for future studies intended to understand the sensitivity of the isolated bacteria to a larger panel of antibiotics and identify plasmids that may be responsible in conferring antibiotic resistance. Whether or not that co-infection with the two bacteria has synergistic pathological consequences in comparison to *E. fergusonii* or *S. gallinarum* infection alone, requires further investigation

Acknowledgments

This study was funded by the Academic Fellowships Fund of the Flemish Association of Educative and Scientific Authors (VEWA) and the National Livestock Research Institute, Mpwapwa, Tanzania.

References

- Devriese, L.A., Poutrel, B., Kilpper-Bälz, R. and Schleifer, K.H. 1983. *Staphylococcus gallinarum* and *Staphylococcus caprae*, new species from animals. *International Journal of Systematic and Evolutionary Microbiology*, 33: 480-486.
- Farmer, J.J.III, Fanning, G.R., Davis, B.R., O'Hara, C.M., Riddle, C. and Hickman-Brenner, F.W. 1985. *Escherichia fergusonii* and *Enterobacter taylorae*, two new species of Enterobacteriaceae isolated from clinical specimens. *Journal of Clinical Microbiology of Clinical Microbiology*, 21: 77-81.
- Forgetta, V., Rempel, H., Malouin, F., Vaillancourt, R. Jr., Topp, E., Dewar, K. and Diarra, M.S. 2012. Pathogenic and multidrug-resistant *Escherichia fergusonii* from broiler chicken. *Poultry Science*, 91(2): 512-25.
- Freney, J., Gavini, F., Ploton, C., Leclerc, H. and Fleurette, J. 1987. Isolation of *Escherichia fergusonii* from a patient with septicemia in France. *European Journal of Clinical Microbiology*, 6(1): 78.
- Galkiewicz, J.P. and Kellogg, C.A. 2008. Cross-kingdom amplification using bacteria-specific primers: complications for studies of coral microbial ecology. *Applied and Environmental Microbiology*, 74(24): 7828-7831.

- Hariharan, H., López, A., Conboy, G., Coles, M. and Muirhead, T. 2007. Isolation of *Escherichia fergusonii* from the feces and internal organs of a goat with diarrhea. *Canadian Veterinary Journal*, 48(6): 630-1.
- Herráez, P., Rodríguez, A.F., Espinosa de los Monteros A., Acosta, A.B., Jaber, J.R., Castellano, J. and Castroa, A. 2005. Fibrino-necrotic typhlitis caused by *Escherichia fergusonii* in ostriches (*Struthio camelus*). *Avian Diseases*, 49(1): 167-9.
- Kolawole, D.O. and Shittu, A.O. 1997. Unusual recovery of animal staphylococci from septic wounds of hospital patients in Ile-Ife, Nigeria. *Letters in Applied Microbiology*, 24: 87-90.
- Lai, C.C., Cheng, A., Huang, Y.T., Chung, K.P., Lee, M.R., Liao, C.H. and Hsueh, P.R. 2011. *Escherichia fergusonii* bacteremia in a diabetic patient with pancreatic cancer. *Journal of Clinical Microbiology*, 49(11): 4001-2.
- Mahapatra, A., Mahapatra, S. and Mahapatra, A. 2005. *Escherichia fergusonii*: An emerging pathogen in South Orissa. *Indian Journal of Medical Microbiology*, 23: 204-204
- Mohamed, O.E. and El Sanousi S.M. 1998. Prevalence and pathogenicity of *Staphylococcus gallinarum* in poultry with special reference to bumblefoot in Khartoum State. PhD thesis at Faculty of Veterinary Department of Microbiology, University of Kartoum.
- Morfin-Otero R., Martínez-Vázquez, M.A., López, D., Rodríguez-Noriega, E. and Garza-González, E. 2012. Isolation of Rare Coagulase-Negative Isolates in Immunocompromised Patients: *Staphylococcus gallinarum*, *Staphylococcus pettenkoferi* and *Staphylococcus pasteurii*. *Annals of Clinical and Laboratory Science*, 42(2): 182-5.
- Rayamajhi, N., Cha, S.B., Shin, S.W., Jung, B.Y., Lim, S.K. and Yoo, H.S. 2011. Plasmid typing and resistance profiling of *Escherichia fergusonii* and other Enterobacteriaceae isolates from South Korean farm animals. *Applied and Environmental Microbiology*, 77(9): 3163-6.
- Savini, V., Catavittello, C., Talia, M., Manna, A., Pompetti, F., Favaro, M., Fontana, C., Febbo, F., Balbinot, A., Di Berardino, F., Di Bonaventura, G., Di Zacomio, S., Esattore, F. and D'Antonio, D. 2008. Multidrug-resistant *Escherichia fergusonii*: a case of acute cystitis. *Journal Clinical Microbiology*, 46(4): 1551-2.
- Tibra, N.K., Jalali, S., Reddy, A.K., Narayanan, R. and Agarwal, R. 2010. Traumatic endophthalmitis caused by *Staphylococcus gallinarum*. *Journal Medical Microbiology*, 59(3): 365-6.
- Yu, D., Chen, Y., Pan, Y., Li, H., McCormac, M.A. and Tang, Y.W. 2008. Case report: *Staphylococcus gallinarum* bacteremia in a patient with chronic hepatitis B virus infection. *Annals of Clinical and Laboratory Science*, 38(4): 401-4.